

W O N D E R W H Y ?

The Use of Prolotherapy for Temporomandibular Joint Dysfunction

Roy V. Hakala, DDS & Kim M. Ledermann, DDS

ABSTRACT

Prolotherapy was first described in the scientific literature in 1937 for the treatment of TMJ disorders. This article describes basic TMJ anatomy and the common components of TMJ dysfunction (TMD). Diagnostic methods used to identify TMD are listed and the technique for injecting the TMJ is detailed. Three case studies are included. A clinical survey of 30 patients treated with Prolotherapy is presented and documents the effectiveness of TMJ Prolotherapy, even in cases refractive to conventional treatment with an intraoral orthosis, physical therapy, home exercises, and dietary restrictions.

Journal of Prolotherapy. 2010;2(3):439-446.

KEYWORDS: Prolotherapy, temporomandibular joint dysfunction, TMD, TMJ.

Temporomandibular joint disorders, commonly known as TMJD or TMD, are endemic in the American population. The National Institute of Health estimates that 10 million Americans are afflicted with some form of TMD that is capable of developing into significant, long-term problems.¹ TMD is frequently a causative agent or a significant aggravating factor in such common symptoms as tension headache, migraine, facial pain, ear pain, and tinnitus; but effective treatment may be difficult to obtain. Even the largest academy dedicated to the diagnosis and treatment of TMD, the American Academy of Craniofacial Pain, has only about 900 members out of the 150,000 currently licensed dentists in the U.S., and only about 15 percent of these members limit their practices to TMD.² Prolotherapy is an effective treatment choice for TMD sufferers who do not have access to other forms of treatment, to those patients who cannot or will not tolerate other treatment plans, and to patients whose conditions do not respond to other treatment modalities.

SYMPTOMS OF TMD

Headache is the most common TMD symptom.³ The temporalis muscle is thickest immediately behind the orbit and contracts each time the teeth are brought together. Tension or spasm in the temporalis muscle frequently is the cause of temple-area headaches and headaches that feel like a piercing pain in the back of the eye.

Migraine, with or without aura, is frequently associated with TMD. Postural compensations for jaw misalignment often produce head and neck protraction. Such faulty posture combined with the unbalanced weight of the head, often ten to fifteen pounds, places a heavy load on the posterior cervical muscles, where many migraines begin.

Facial pain is a common result of tension or trigger point development in the masseter muscles that extend from the zygomatic arch ("cheekbone") to the lower and posterior border of the jaw. The masseter muscles are the primary elevators of the jaw when eating and bring the teeth into contact before the temporalis muscles contract. TMD-related jaw misalignment often results in parafunction of the masseters, with pain extending over the lower half of the face.

Temporomandibular joint (TMJ) pain is an obvious sign of TMD but is usually found on palpation, rather than a chief complaint. TMD sufferers quickly learn that chewing certain types of food is painful, and modify their diets so as to minimize frank joint pain. Conversely, some TMD sufferers often discover that it feels better to keep something such as chewing gum between their teeth, minimizing compression of painful structures within the TMJs. Without a physical examination that includes TMJ palpation, TMD diagnosis is easily missed.

Restricted jaw movement, irregular jaw movement, and TMJ sounds such as clicking, popping, or crepitation are obvious symptoms of TMD, but patients may mask these symptoms. Eating only soft foods and limiting mouth opening by taking only small bites can prevent noticeable joint noise. Also, patients with minor joint sounds may not perceive these noises to be abnormal unless the noise is accompanied by pain.

Otalgia and tinnitus are reported by as many as 65 percent of TMJ sufferers⁴, due to the close proximity of the external auditory meatus to the TMJ and to tension on structures such as the discomalleolar and malleomandibular ligaments.⁵ However, patients with ear symptoms rarely perceive a connection between their ear symptoms and symptoms of TMD. Such patients often go through repeated courses of antibiotics for suspected ear infections and may have had extensive ear imaging before being referred for a TMJ evaluation.

TMJ EXAMINATION

A few basic diagnostic procedures can identify most cases of TMD. These include:

- Firm bilateral palpation of temporalis muscles in the anterior, middle, and posterior segments.
- Firm bilateral palpation of the masseter muscles at their zygomatic origins, at their mid-bellies, and at their insertions on the mandible.
- Light palpation over both TMJs during maximal opening and closing to detect joint noises and irregularity in movement.
- Firm palpation with the small fingers in the patient's ears as the patient opens and closes the mouth.
- Measurement of maximum interincisal opening, which is normally in the range of 48-52 millimeters, sometimes approximated as "three finger widths."
- Observation to determine if jaw movements are smooth, linear, and free of pain.

When checking for joint sounds, avoid using a stethoscope. Stethoscopes are of a specific length to optimize detection of heart sounds, rarely pick up significant TMJ sounds, and can lead to false negative conclusions. If palpation does not provide definitive results such as clicking or crepitation, closer examination with either an obstetric or vascular Doppler may be helpful.

TMD TREATMENT

Parafunctional jaw habits, such as chewing pencils or fingernails or excessive gum chewing, can aggravate TMD. Stress often is blamed as a causative agent. Encouraging the patient to discontinue non-functional jaw activities and work on stress reduction may provide some benefit, especially in cases with smooth joint

function and only minor facial muscle pain;⁶ however, jaw parafunction and stress have never been proven to cause internal TMJ derangement. Orthodontic treatment often is recommended for TMD sufferers, but the literature shows no relationship between malocclusion and TMD.⁷

Effective treatment of all but the most minor cases of TMD requires some understanding of the joint anatomy and function.

TMJ ANATOMY

The TMJ fossa ("glenoid fossa") is located in the temporal bone, immediately anterior to the ear. The tympanic plate of bone between the ear and the TMJ fossa is very thin, almost to the point of being transparent when observed surgically. This thin plate of bone is not suited to bearing any significant load and, in a healthy joint, the mandibular condyle remains a few millimeters anterior to it, even during forceful chewing. The retrodiscal tissues are uncompressed and the retrodiscal ligaments stabilize the posterior aspect of the disc.

The anterior slope of the glenoid fossa is thick and capable of supporting masticatory pressure on the condyle. The mandibular condyle normally is separated from this part of the fossa by the fibrous (not cartilaginous) disc, which moves with the condyle during all jaw movements. This disc is loosely attached and remains properly positioned between the condyle and fossa due to its biconcave shape that closely adapts to the convexity of the condyle and the eminence, and by peripheral ligaments that normally limit its movement. (See Figure 1.)

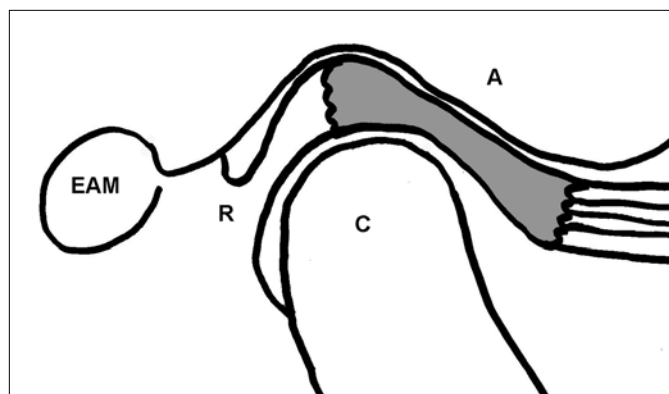


Figure 1. Schematic representation of normal TMJ. The disc (gray) maintains alignment between the articular slope and eminence (A) and the condyle (C). The condyle remains well-separated from the external auditory meatus (EAM) with no significant pressure on the retrodiscal tissues (R).

TMJ INTERNAL DERANGEMENT

Since the disc is not adherent to either the condyle or fossa, it can be displaced by various factors including trauma. Low-grade, long-term trauma such as a significant malocclusion can thin the margins of the disc and cause it to lose stability. Direct trauma such as a blow to the jaw can cause joint misalignment and disc displacement. So-called “indirect trauma” involving violent acceleration and deceleration of the head and jaw has been shown to damage the restraining ligaments and allow disc displacement and misalignment of the joint. (See Figures 2 & 3.) One magnetic resonance imaging (MRI) study suggested that as many as two-thirds of patients who receive a significant cervical acceleration/deceleration neck injury (“whiplash”) suffer concurrent TMJ injuries.⁸

Disc displacement is often in the anterior or anteromedial direction with reciprocal posterior displacement of the mandibular condyle into the retrodiscal tissues, adjacent to the external auditory meatus. (See Figure 4.) During mouth opening, the condyle first rotates and then translates forward, often with a perceptible click as the condyle passes over the posterior border of the disc.

After an unpredictable period of jaw clicking on opening, the ligaments may become so injured and lax that the disc remains out of place, obstructing the condyle and limiting jaw movement. This joint condition is commonly referred to as “closed lock.” The joint becomes quieter

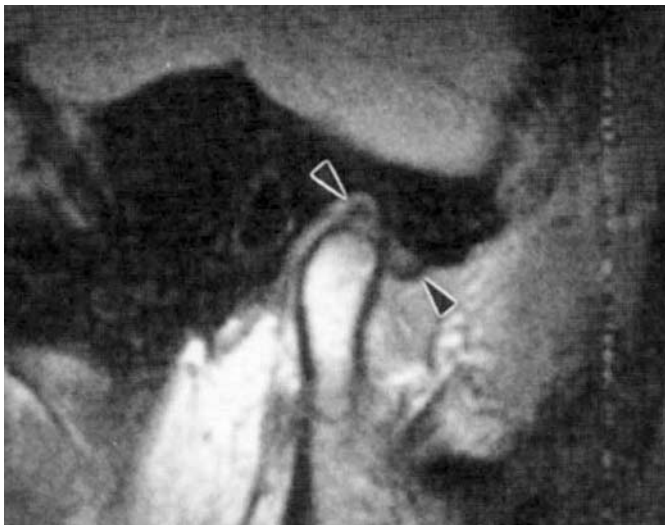

Figure 2. This MRI reveals normal “bow tie” disc anatomy and placement from the twelve o’clock to three o’clock position (between arrows), anterosuperior to the condyle.

Magnetic resonance images courtesy of Imaging Systems, Inc., of Peachtree City, GA.

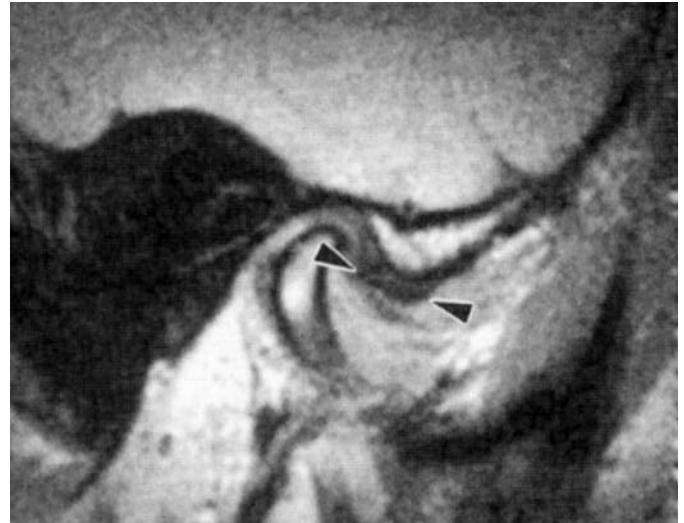

Figure 3. This MRI shows a distorted disc (between arrows) that is displaced anteriorly and inferiorly to the condyle. Reciprocally, the condyle is displaced posteriorly into the retrodiscal tissues adjacent to the external auditory meatus.

Magnetic resonance images courtesy of Imaging Systems, Inc., of Peachtree City, GA.

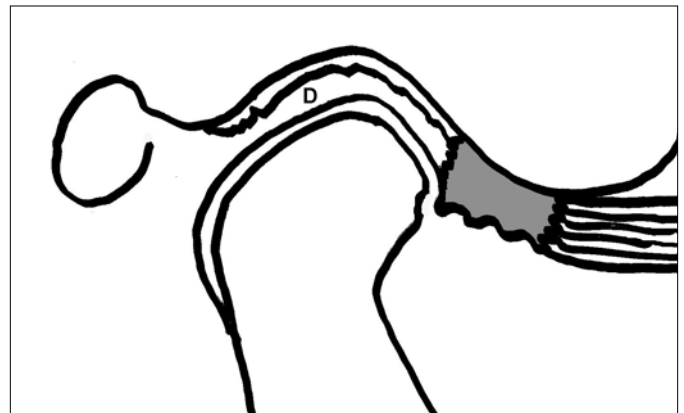


Figure 4. The disc has displaced anteriorly and become distorted. The condyle is beginning to remodel and develop a “beak” on its anterior surface. The extended and disrupted retrodiscal ligaments (D) can no longer stabilize the disc.

at this point but the posteriorly displaced condyle may eventually perforate the retrodiscal tissues, resulting in bone-on-bone contact and degenerative condylar changes. (See Figure 5.) Pain levels vacillate with the progression of this internal joint derangement.

TREATMENT STRATEGIES

The most common treatment approach to TMD is construction of an intraoral nightguard. Such appliances protect the teeth but do not necessarily realign the displaced structures within the TMJ. Even if alignment is

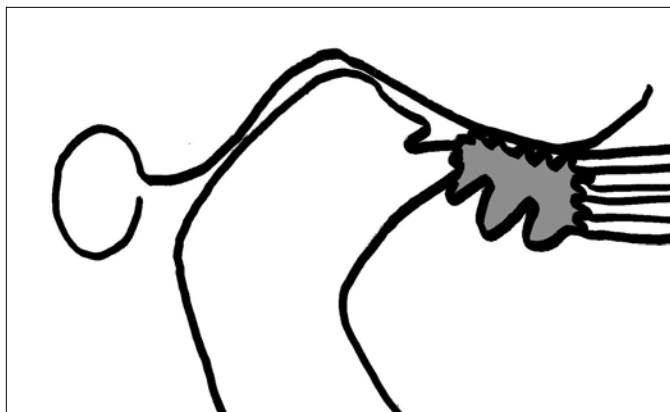

Figure 5. The condyle has perforated the retrodiscal tissues and begun to place pathologic pressure on the tissues between the condyle and the ear, often producing various types of otalgia and/or tinnitus. The disc and anterior surface of the condyle have undergone severe degenerative change.

achieved overnight, leaving the appliance out during the day allows joint misalignment during waking hours and the degenerative process within the joint may continue. Furthermore, bulky appliances may intrude on tongue space and compromise both comfort and breathing, and rubbery appliances often encourage bruxism, which can aggravate the myogenous pain of the disorder.⁹

TMJ surgery is indicated only in cases with no other practical alternative and is generally considered as a last resort. No fully functional total TMJ replacement joint is available and synthetic TMJ discs were removed from the market in 1991. Discectomy may relieve pressure on the painful structures within the joints but, without discs, the joints and occlusion are unstable and these patients often have recurrent pain and dysfunction.¹⁰

Orthodontic treatment or prosthodontic (crown and bridge dentistry) treatment is sometimes used to establish functional dental occlusion, but this treatment is not normally done until the TMJs have been stabilized in a comfortable and functional position by other means.^{11, 12}

Physical therapy by a practitioner knowledgeable about TMJ anatomy and function can be very helpful, but such improvement tends to be limited and short-term if the intracapsular TMJ structures cannot be aligned and stabilized.

Occlusal orthotics that are worn over the teeth 24 hours a day and have an occlusal surface that realigns the condyles and discs within their fossae can be very effective, but not

all patients are willing or able to wear such appliances on a full-time basis. Also, some discs remain unstable even after many months of use of such an appliance.¹³

PROLOTHERAPY AS TMJ THERAPY

The first published article on Prolotherapy, short for “proliferation injection therapy” and now also known as regenerative injection therapy (RIT), focused on treating the TMJ.¹⁴ As readers of this journal undoubtedly know, the basic principle of Prolotherapy is to inject a substance that will cause a low-grade inflammatory process within the joint, drawing in fibroblasts that strengthen the attachments of tendons and ligaments. The process stabilizes the joint, improves the range of motion in a hypomobile joint, helps prevent dislocation in a hypermobile joint, and relieves pain.

Prolotherapy has been an important adjunct to TMD treatment in our office. While we work extensively with intraoral orthoses, physical therapy, home exercises, and dietary restrictions, not all patients respond optimally. Some patients are reluctant or unable to wear an intraoral appliance full-time because such appliances can interfere with speech. This means that many teachers, salespeople, receptionists, and others who speak for a living are reluctant to wear an orthosis during the day, or simply refuse to do so. Physical or mental handicaps can prevent some patients from being able to care for, or function with, an intraoral appliance. Some disc displacements are so severe that an intraoral appliance cannot reasonably be made to the dimensions necessary to recapture the discs. Some patients with particularly lax or damaged ligaments experience pain relief while wearing the orthosis, but pain and joint noise returns as soon as the appliance is removed. Prolotherapy can be effective in all such cases.

TECHNIQUES FOR TMJ PROLOTHERAPY

The face and TMJ are highly innervated and sensitive areas. Injections in this area must be as atraumatic as possible. To this end, we routinely use a 30-gauge, one-inch needle. We also use a dextrose solution whenever possible, as it causes less post-injection soreness than fish oil or pumice, and pumice is difficult to express through a 30-gauge needle. Compounding pharmacies can provide pre-mixed solutions, but we mix our solutions directly in the syringe. This consists of drawing up 0.75mL of 50% dextrose, 0.75mL of bacteriostatic water, and 1.5mL of 2% lidocaine into a 3-mL syringe for each TMJ.

Using a 25-gauge needle to draw up the solutions speeds the process, then the needle is changed to 30-gauge and the syringe is shaken and the air expressed. The result is a dextrose concentration of approximately 12.5%. The precise concentration of dextrose is not critical so long as it is strongly hypertonic and causes adequate cell wall lysis to attract fibroblasts and begin the regenerative process.

Since TMJ disc displacement usually is anterior, our priority is to accomplish repair of the extended or torn posterior disc attachment. We locate the posterior joint space by cleansing the skin immediately anterior to the ear with alcohol and palpating the lateral pole of the condyle as the patient opens and closes. (See *Figure 6*.) The target is the depth of the depression that forms immediately anterior to the tragus of the ear as the condyle translates forward and down. This can be marked with a washable felt-tip pen, if desired. (See *Figure 7*.) Then, a disposable bite block is placed between the patient's anterior teeth to keep the patient from closing the condyle back into the fossa and onto the needle. The injection needle penetrates the skin at the marked point and is directed medially and slightly anteriorly to avoid penetration into the ear. Surface skin and connective tissue is deceptively thick in this location and the needle usually penetrates to, or nearly to, its full one-inch length before encountering the medial wall of the fossa. Slight negative pressure is exerted on the plunger to confirm that the needle tip is not in a vessel, even though no vessels of any size are expected to be encountered within the fossa. One mL of Prolotherapy solution is deposited here. (See *Figure 8*.)

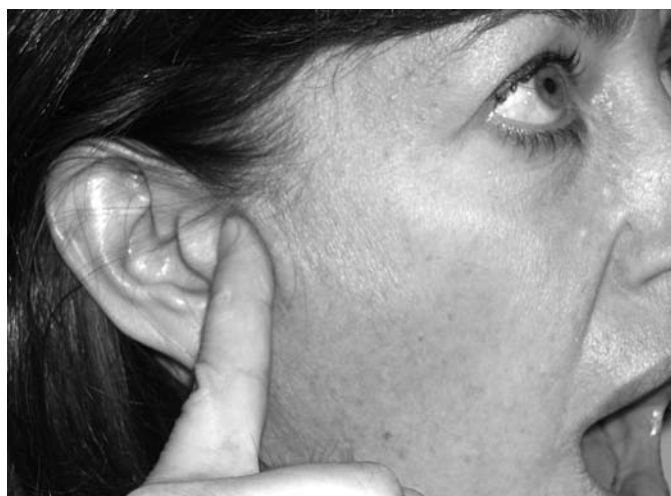

Figure 6. Palpation of the TMJ fossa posterior to the translated condyle with mouth wide open.

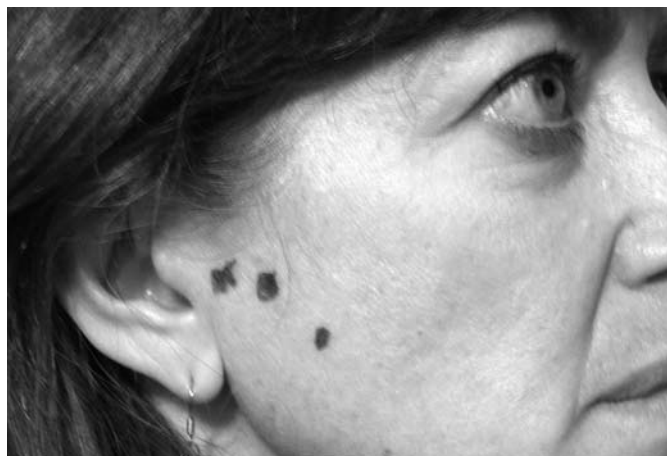

Figure 7. Marked injection sites.

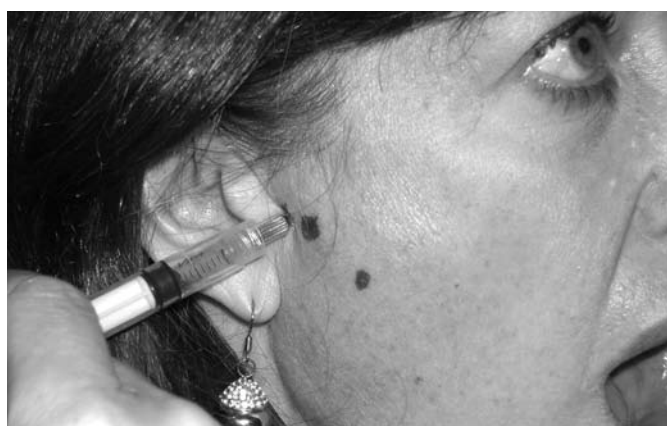

Figure 8. Angle and depth for injection of posterior joint space with a one-inch needle, behind the translated condyle and into the depth of the fossa.

The second target is the anterior disc attachment, where the disc connects to the superior portion of the lateral pterygoid muscle. This muscle often is foreshortened or in spasm in cases of chronic disc displacement. Injecting the Prolotherapy solution here can strengthen the tendinous attachment of this muscle to the disc at the same time the anesthetic component anesthetizes and elongates the muscle, which can allow the disc to reposition itself over the condyle and often produces an immediate reduction in TMJ clicking. We locate this target area at the same time we palpate the location of the posterior joint space, note the location of the slight depression just anterior to the condyle when the mouth is closed, and mark this point with washable ink. Marking this point before injecting the posterior aspect of the joint is advisable, as it becomes much more difficult to palpate this depression after the posterior joint recess has been injected. For this injection, the bite block is removed and the patient is instructed to

close gently, moving the condyle back into the fossa. We insert the needle at the marked point, again directing the tip medially and angulated slightly anteriorly to, or nearly to, its full one-inch length. Aspiration is performed and another 1mL of Prolotherapy solution is injected here.

Most TMD patients have some chronic masseter tension and pain with resultant strain on its attachment to the zygomatic arch. The third mL of Prolotherapy solution is used to address this problem. We palpate the masseter attachment along the inferior border of the zygomatic arch at the same time that we palpate and mark the posterior and anterior aspects of the condyle, and mark the area of the masseter that is most tender to palpation. Asking the patient to clench the teeth makes the masseter stand out, and the area that is most rigid to palpation is usually the most tender as well. The patient is told to relax the jaw, and the final mL is injected directly into this area, again at or near the full one-inch length of the needle.

The injection sites are wiped with alcohol, which removes the washable ink as well, and a pulse is taken for the medical record and to confirm that the patient has relaxed and is ready for discharge.

Our standard program is to repeat the injections three times, at two-week, four-week, and six-week intervals. This totals four injection appointments over twelve weeks. We palpate the joints for pain and noise, and palpate the affected muscles for pain, at each appointment. We also measure the range of jaw motion interincisally and record all these findings. Patients typically report some improvement after the first injection appointment but often have some increased discomfort shortly before the second appointment. The following appointments generally produce more benefit, quieter joints, and symptom relief without rebound. We expect the healing process to continue for at least twelve more weeks and schedule a final recall three months out.

COMPLICATIONS

Dextrose is a corn product and must not be used in patients with a corn allergy. Also, an alternative local anesthetic must be used in patients who are allergic to lidocaine.

At the one-inch depth of needle penetration, the areas described above have no major blood vessels and intravascular injections are not a significant risk with this

technique, especially if aspiration is performed before each injection. Some authorities have stated that the lumen of a 30-gauge needle is too small to admit red blood cells, but clinical experience in injecting other, more vascular areas has shown that blood can easily be drawn up through this small needle. On rare occasion, the local anesthetic will diffuse forward and partially paralyze the lower eyelid. When this happens, it is immediately apparent and the patient is told to make a conscious effort to blink that eye frequently for the next hour or so, until the anesthetic effect diminishes, to lubricate the eye and prevent a corneal abrasion. Fair-skinned patients may display some minor bruising for a day or two but this is more common if the operator has difficulty locating landmarks and moves the needle laterally after insertion. The most common side effect is a temporary change in the dental occlusion. Until the 2mL of injection solutions dissipates from the joint, which may take one to four days, the condyle will rest lower in the fossa and the posterior teeth may not fully occlude. It is important to warn the patient that this is likely, and to be careful to chew food carefully and thoroughly before swallowing.

CASES

Case #1 is a 49-year-old female. Her original chief complaints included temporalis-area headaches one to two times per week, bilateral facial pain that was worse on the left side, and bilateral TMJ clicking. Symptoms were not known to be related to any particular incident or injury and had been present for about four years prior to her initial examination in our office. She had a good range of mandibular motion at baseline. She was treated with a home care program, therapy, and wore an intraoral orthosis for four months with some success. The most significant improvement was reduction of her headaches, but TMJ clicking indicative of persistent disc displacement, and intermittent facial pain remained.

A series of four Prolotherapy appointments was carried out over twelve weeks, as previously described above. On follow-up 11 weeks later, her mandibular range of motion remained good and her maximum mandibular protrusion had increased from five millimeters to 10 millimeters. The patient reported that she was feeling much better as her facial pain and TMJ clicking had dissipated. Very minimal masseter discomfort was elicited on firm palpation. Mild intermittent clicking was palpable in the left TMJ but the patient reported that this was steadily diminishing.

Case #2 is a 56-year-old female who presented to our clinic in chronic closed lock. She had TMJ clicking for several years and her jaw became locked four months prior to her initial examination at our clinic. Chief complaints include limited ROM and throbbing pain in the left TMJ, which had begun spreading over her lower face and into both temples. Her maximum opening at the initial exam was about half of normal at only 29 millimeters with deflection of her jaw to the left on opening. Use of an intraoral orthosis along with home care and physical therapy over three months produced only minor improvement with myalgia and slight improvement in range of movement.

A series of Prolotherapy appointments was carried out as described above but only to the left TMJ and masseter muscle. By the fourth visit, maximum opening had improved to 38 millimeters and lateral and protrusive range of movement had improved as well. Headache and facial pain had resolved and no significant tenderness was reported on palpation of the left TMJ or temporalis or masseter muscles.

Case #3 is a 23-year-old male who presented with audible and palpable clicking in the left TMJ, accompanied by pain that he rated at 3-4 on a scale of 5. Treatment alternatives were presented and treatment with an intraoral orthosis to be worn full-time for four to six months was recommended. The patient declined this treatment plan as he worked as a professional model and was concerned that wearing a dental appliance would adversely affect his facial appearance. He opted for Prolotherapy, which was done at four separate appointments over a 12-week interval. At three-month recall, both the TMJ clicking and the joint pain were completely gone.

STATISTICS

Chart review of the most recent 30 patients treated with Prolotherapy demonstrates significant therapeutic benefit. All 30 of these patients had unilateral or bilateral TMJ clicking in a total of 55 joints. All clicking was easily palpable and reported pain on firm preauricular palpation of these joints averaged a level of 2.8 on a scale of 5, and these signs and symptoms had persisted despite at least 5 months of treatment with an intraoral orthosis, home exercises, and dietary restrictions. It should be noted that these patients were essentially refractory to such typical nonsurgical care.

All of these patients in this audit received Prolotherapy injections in the affected joints and ipsilateral masseter muscle origins at four separate appointments over an average of 14.2 weeks. At 12-week recall, 43 joints (78%) had substantial improvement in clicking (no longer detectable by clinical palpation and perceptible only as reported by the patient) and 32 had completely quit clicking (no clicking perceptible by palpation or by patient report). The palpation pain report had improved to a level of 1 or less on a scale of 5, in 39 joints (71%), and had reached a level of zero in 23 joints (42%). None of these patients had any significant bruising, and only one had an event of paresis of the lower eyelid, which lasted approximately 90 minutes.

DISCUSSION

In our office, Prolotherapy is used most often for patients who have been refractory to treatment with an intraoral orthosis, physical therapy, dietary restrictions, and home care. Our clinical results in our office indicate that Prolotherapy can be very effective, even in these difficult patients. We speculate that Prolotherapy success would be even greater when used in milder cases of TMD but we do not yet have the statistics to support this hypothesis. Continued research into Prolotherapy effectiveness in patient populations with varying histories, symptom sets, and levels of TMD severity is needed.

SUMMARY

TMJ Prolotherapy has been performed in various clinical settings for more than 70 years. This technique continues to demonstrate its safety and effectiveness, even in patients who do not respond adequately to other forms of nonsurgical therapy. ■

BIBLIOGRAPHY

1. <http://www.nidcr.nih.gov/OralHealth/Topics/TMJ/>.
2. <http://www.aacfp.org/referral.html>.
3. Abrahansson C, et al. TMD in consecutive patients referred for orthognathic surgery. *Angle Orthodontist*. 2009;79(4):621-7.
4. de Felício CM, et al. Otologic symptoms of temporomandibular disorder and effect of orofacial myofunctional therapy. *Cranio*. 2008;26(2):118-25.
5. Sencimen M, et al. Anatomical and functional aspects of ligaments between the malleus and the temporomandibular joint. *International Journal of Oral and Maxillofacial Surgery*. 2008 37(10):943-947.

6. Glaros A, et al. The role of parafunctions, emotions and stress in predicting facial pain. *Journal of the American Dental Association*. 2006;136(4):451-458.
7. McNamara J. Orthodontic treatment and temporomandibular disorders. *Oral Surgery, Oral Medicine, Oral Pathology, Oral Radiology and Endodontology*. 1997;83(1):107-117.
8. Pressman B, et al. MR imaging of temporomandibular joint abnormalities with cervical hyperextension/hyperflexion (whiplash) injuries. *Journal of MRI*. 1992;2(5):569-574.
9. Narita N, et al. Effects of jaw clenching while wearing an occlusal splint on awareness of tiredness, bite force, and EEG power spectrum. *Journal of Prosthodontic Research*. 2009;53(3):120-5.
10. Trumpy IG, et al. Surgical treatment of internal derangement of the temporomandibular joint: long-term evaluation of three techniques. *Journal of Oral and Maxillofacial Surgery*. 1995;53(7):740-6; discussion 746-7.
11. Greene CS. Orthodontics and the temporomandibular joint. *Angle Orthodontist*. 1982;52:66-172.
12. Okeson J, ed. *Orofacial Pain: Guidelines for Assessment, Diagnosis and Management*. Carol Stream, IL, Quintessence; 1996:154-155.
13. Badel T, et al. A quantitative analysis of splint therapy of displaced temporomandibular joint disc. *Annals of Anatomy*. 2009;191(3):280-7.
14. Schultz L. A treatment for subluxation of the temporomandibular joint. *JAMA*. 1937;25:1035-7.